



ISSN (P): 2617-7226  
ISSN (E): 2617-7234  
[www.patholjournal.com](http://www.patholjournal.com)  
2020; 3(1): 302-304  
Received: 20-11-2019  
Accepted: 23-12-2019

**Dr. Manjula K**  
Associate Professor,  
Department of Pathology,  
SDUMC. Sri Devaraj Urs  
Medical College, Tamaka,  
Kolar, Karnataka, India

**Dr. Kalyani R**  
Department of Pathology,  
SDUMC. Sri Devaraj Urs  
Medical College, Tamaka,  
Kolar, Karnataka, India

**Dr. Harish Kumar**  
Department of Pathology,  
SDUMC. Sri Devaraj Urs  
Medical College, Tamaka,  
Kolar, Karnataka, India

**Corresponding Author:**  
**Dr. Manjula K**  
Associate Professor,  
Department of Pathology,  
SDUMC. Sri Devaraj Urs  
Medical College, Tamaka,  
Kolar, Karnataka, India

## Spectrum of lesions in urinary bladder biopsies: A histopathological study

**Dr. Manjula K, Dr. Kalyani R and Dr. Harish Kumar**

**DOI:** <https://doi.org/10.33545/pathol.2020.v3.i1e.189>

### Abstract

The lesions of the urinary bladder are responsible for significant morbidity and mortality. Non neoplastic lesions are more disabling than lethal<sup>1</sup>. Urinary bladder cancer is the sixth most common cancer worldwide and the second most common malignancy of the genitourinary tract after prostate cancer. Among bladder tumors, urothelial carcinoma is the commonest accounting for 90% of all the primary tumors of the bladder. Cystoscopy is the primary diagnostic tool for the patients with suspected bladder tumor. It allows a direct visualization of the bladder mucosa and taking biopsy from the suspected mucosal lesion. Cystoscopic evaluation and histopathological analysis of biopsy material are the backbone of bladder cancer diagnosis and treatment. Present study is conducted to study histopathological features of various lesions of urinary bladder, frequency of bladder lesions and to correlate clinical details with histopathological findings.

**Keywords:** cystoscopy, urothelial carcinoma, histopathology, bladder lesions

### Introduction

The lesions of the urinary bladder are responsible for significant morbidity and mortality. Non neoplastic lesions are more disabling than lethal<sup>[1]</sup>. Urinary bladder cancer is the sixth most common cancer worldwide and the second most common malignancy of the genitourinary tract after prostate cancer<sup>[2]</sup>. Among bladder tumors, urothelial carcinoma is the commonest accounting for 90% of all the primary tumors of the bladder. Cystoscopy is the primary diagnostic tool for the patients with suspected bladder tumor. It allows a direct visualization of the bladder mucosa and taking biopsy from the suspected mucosal lesion. Cystoscopic evaluation and histopathological analysis of biopsy material are the backbone of bladder cancer diagnosis and treatment<sup>[3, 4, 5]</sup>.

Present study is conducted to study histopathological features of various lesions of urinary bladder, frequency of bladder lesions and to correlate clinical details with histopathological findings.

### Methods

After obtaining ethical clearance from the institution available patient's clinical and cystoscopic finding details were collected from the medical records of patients who underwent transurethral resection of bladder (TURBT) from January 2008 to December 2018 were collected.

**Inclusion criteria:** All the Cystoscopic biopsies and TURBT biopsies received in the department of Pathology

**Exclusion criteria:** Auto lysed specimen, inadequate biopsies

Gross and microscopic findings of all the cases were reviewed in details. Slides were reviewed to study the following histopathological details. Histologic grade, type, invasion into lamina propria, invasion into muscularis propria, lymphatic invasion and blood vessel invasion, stage of the tumor and other changes. Clinical and cystoscopic details were correlated with histopathological findings and analyzed.

### Results

147 bladder biopsies were included in the present study. Neoplastic lesions were more

common accounting to 84.35%, rest were non neoplastic (15.65%). 93% were males and 7% were females (2.26:1). The peak age group of incidence was seen in 51-60 years, followed by 61-70years (Figure 1). Painless haematuria was the most common clinical presentation, followed by urinary tract infection and dysuria (Figure 2). The most common cystoscopic finding was grey white soft tissue growth followed by thickening of bladder mucosa. The most common lesion in our study was noninvasive low grade urothelial carcinoma followed by noninvasive high grade urothelial carcinoma (Figure 4). 14.96% of urothelial neoplasms showed muscle invasion. Muscle invasion was more common with high grade carcinoma. Among non-neoplastic lesions of bladder, chronic nonspecific cystitis is the commonest accounting to 10.88% followed by granulomatous cystitis (2.72%).

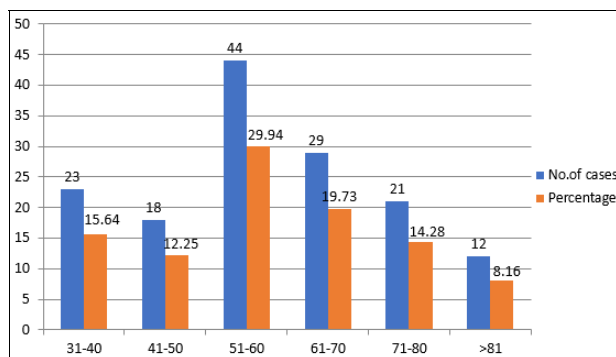


Fig 1: Age distribution

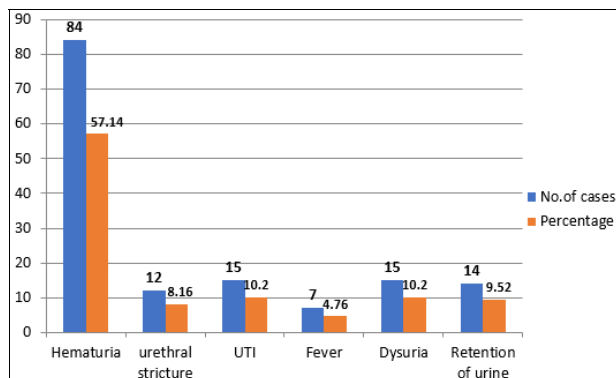


Fig 2: Clinical presentation

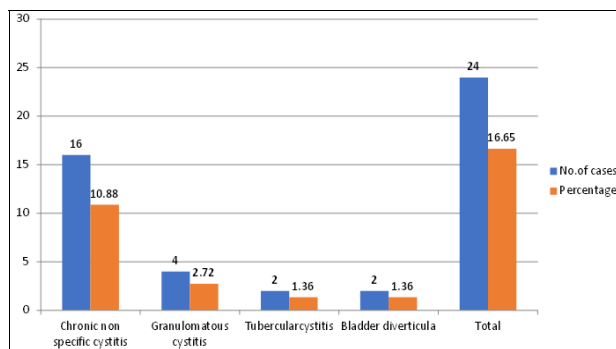


Fig 3: Benign lesions in urinary bladder

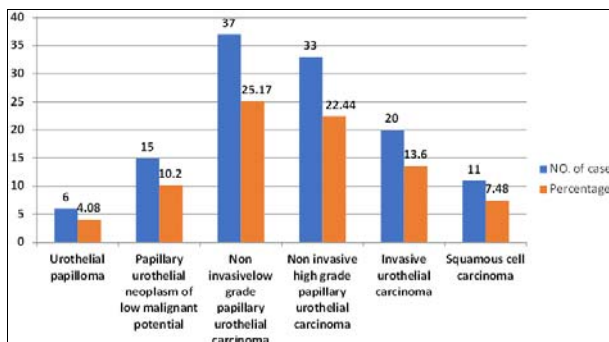


Fig 4: Neoplastic lesion of urinary bladder

**Discussion**

Urinary bladder lesions are responsible for significant morbidity and mortality [1]. urothelial carcinoma is the 6<sup>th</sup> most common cancer worldwide [2]. Cystoscopy is the primary investigation to diagnose bladder lesion and rule out bladder cancers in suspected cases. histopathological examination of bladder biopsies not only gives the diagnosis but also provides information to the Urologist to plan treatment. Diagnosis and monitoring of bladder lesions are made by combining cystoscopic and histopathological findings [2, 3].

147 bladder biopsies were analyzed in the present study. Haematuria (57.14%) was the most common clinical presentation. Dysuria and urinary tract infection were accounted to 10.20%. These findings are slightly lower than that reported in the literature [5, 6].

In our study male to female ratio was 2.26:1, which is similar to study done by Anitha *et al.* [2], Goyal *et al.* [5] and Vaidya *et al* [6]. In our study the most common age group of presentation of neoplastic lesions of the bladder were 51- 60 years. In similar studies the most common age group was 60-70 years [2, 5, 6]. Non neoplastic lesions were accounted to 15.65% (24 cases). The most common condition was chronic cystitis (10.88%). tuberculous cystitis was seen in 2 cases. these findings are correlating with Srikoustubha *et al.* [1].

Out of 123 neoplastic lesions, 112 cases were urothelial neoplasms, 11 cases were squamous cell carcinoma and one case was metastatic squamous cell carcinoma from cervix.

Noninvasive low grade papillary urothelial carcinoma was the commonest accounting to 25.17 % ( 37 cases) followed by high grade urothelial carcinoma, similar to study done by Oosterhuis *et al.* [7].

In our study 14.96% of urothelial neoplasm showed muscle invasion. Muscle invasion in other similar studies muscle invasion varies from 26-35.8% [6, 8, 9, 10].

**Conclusion**

Neoplastic lesions were more common. Most common age group was 51-60 years. Noninvasive low grade papillary urothelial carcinoma was the commonest urothelial neoplasm. 61.89% of urothelial neoplasms were noninvasive at the time of presentation. Muscle invasion directly correlates with grade of the tumor. Histological grade, presence or absence of muscle invasion are the most important histological findings in deciding the treatment and prognosis of bladder malignancies.

**Reference**

1. Srikousthubha, Sukesh CVR, Hingle S. Profile of lesions in cystoscopic bladder biopsies: A histopathological study. *J Clin Diagn Res.* 2013; 7(8):1609-1612.
2. Shah A, Srivastava M, Samdurkar A, Sigdel G. Spectrum of Lesions in Urinary Bladder: A Histopathological Study. *Journal of Universal College of Medical Sciences.* 2018; 6(2):24-27.
3. Sathya Mylsamy, Devaki Kanakasabapathi. Histopathological Study TURBT Biopsies of Urinary Bladder Cancer. *Trends in Medical Research.* 2017; 12:51-54.
4. Susmitha S, Patil GS, Patil SB. A Study on Histopathological Spectrum of Lesions in Urinary Bladder Specimens. *Annals of Pathology and Laboratory Medicine.* 2018; 5(5):489-494.
5. Goyal VK, Vyas SP, Kothari DC. Spectrum of Lesions in Urinary Bladder Biopsies: Histopathological Study. *Int. J Dent Med Res.* 2015; 1(6):42-46.
6. Vaidya S, Lakhey M, Sabira KC, Hirachand S. Urothelial tumours of the urinary bladder: a histopathological study of cystoscopic biopsies. *JNMA.* 2013; 52(191):475-8.
7. Oosterhuis *et al.* Histological grading of papillary urothelial carcinoma of the bladder: prognostic value of the 1998 WHO/ISUP classification system and comparison with conventional grading systems. *J Clin Pathol.* 2002; 55:900-905.
8. Shah A, Srivastava M, Samdurkar A, Sigdel G. Spectrum of Lesions in Urinary Bladder- A Histopathological Study. *J Univers Coll Med Sci.* 2018; 6(2):24-27.
9. Viadya S, Lakhey M, KC S, Hirachand S. Urothelial tumors of the urinary bladder: a histopathological study of cystoscopic biopsies. *J Nepal Med Assoc.* 2013; 52:475-8.
10. Biswas RR, Mangal S, Guha D, Basu K, Karmakar D. An epidemiological study of cases of urothelial carcinoma of urinary bladder in a tertiary care centre. *Journal of Krishna Institute of Medical Sciences.* 2013; 2:82-8.
11. Gupta P, Jain M, Kapoor R, Muruganandham K, Srivastava A, Mandhani A. Impact of age and gender on the clinicopathological characteristics of bladder cancer. *Indian J Urol.* 2009; 25:207-10.