



E-ISSN: 2395-1958
P-ISSN: 2706-6630
IJOS 2020; 6(2): 243-247
© 2020 IJOS
www.orthopaper.com
Received: 20-02-2020
Accepted: 22-03-2020

Roger Kennedy X
Junior Resident, Department of
Orthopaedics, Sri Devaraj Urs
Medical College, Sduaher, Kolar,
Karnataka, India

Arun HS
Professor and Head of,
Department of Orthopaedics, Sri
Devaraj Urs Medical College,
Sduaher, Kolar, Karnataka,
India

Corresponding Author:
Arun HS
Professor and Head of,
Department of Orthopaedics,
Sri Devaraj Urs Medical
College, Sduaher, Kolar,
Karnataka, India

A prospective study on role of hydraulic distension along with steroid under local anaesthesia in the management of frozen shoulder

Roger Kennedy X and Arun HS

DOI: <https://doi.org/10.22271/ortho.2020.v6.i2d.2046>

Abstract

Introduction: Frozen shoulder” is a chronic condition characterized by gradually progressive, painful restriction of all shoulder joint movement, with slow spontaneous recovery of either partial or complete movement over a period of time. Although many treatment options have been proposed for the frozen shoulder syndrome, each has limitations. Hydro dilation technique was developed in order to loosen the reported contraction and adhesion. we evaluated the Range of movement and pain relief of shoulder following “Hydraulic distension under local anaesthesia along with a steroid” pre and post distension.

Material and methods: A prospective observational study was conducted in the department of orthopaedics at RLJ hospital attached to Sri Devaraj Urs Medical College between June 2018 to November 2019 for a period of 1.5 year. All the Patients with Peri arthritis shoulder and age above 30 years were included in the study. After obtaining the informed consent from the patients, Demographic data, History, Clinical Examination and details of investigations were recorded in study proforma. The pain and functional scoring used as per “The society of American Shoulder and elbow surgeons” and follow-up was done at 3 weeks, 6 weeks and 12 weeks after procedure. IBM SPSS version 22 was used for statistical analysis.

Results: Total 50 patients were included in the study. The average age of the study population was 52.68 ± 9.79 . There were no patients with complete disability. Marked pain (grade 1) was observed on presentation in 46(92%) of the subjects. Post distension only 9(18%) had pain. Flexion, abduction, internal rotation, external rotation movements of the shoulder have improved post distention and were statistically significant at 3rd, 6th, 12th week. The mean ASES was 36.04 ± 5.84 at base line, it was 67.6 ± 7.64 at 6th week and 91.04 ± 8.68 at 12th week. The differences in the ASES score at 6th week and 12th week follow up period with baseline value were statistically significant (P value <0.001).

Conclusion: Hydraulic distension is a safe, reliable, cost effective modality in treating the chronically distressing painful condition of frozen shoulder.

Keywords: Hydraulic distension, local anaesthesia, frozen shoulder

Introduction

“Frozen shoulder” is a chronic condition characterized by gradually progressive, painful restriction of all shoulder joint movement, with slow spontaneous recovery of either partial or complete movement over a period of time [1]. The first recorded description of a frozen shoulder was reported by Duplay in 1872 in his description of a “peri arthritis scapulohumeral” and the word ‘frozen shoulder’ was first coined by Codman in 1934 [2]. He described the symptoms to be slow onset of pain felt near the insertion of the deltoid muscle, inability to sleep on the afflicted side, and limited active and passive elevation and external rotation, yet with a normal radiological appearance.

The best techniques of conservative management of adhesive capsulitis has included combinations of regimens that include physiotherapy utilising a number of techniques, hydraulic distension of the glenohumeral joint and intra-articular steroid injections. While in operative management point of view, Arthroscopic capsular release had immediate recovery of function and earlier return to work.

Although variety of treatment options have been reported for the frozen shoulder syndrome, each has its disadvantages. Improvement with Home exercises may not alter the rate of natural

recovery. Significant complications have been documented with Manipulation under anesthesia but significant and publications report protracted recovery [3]. Poor outcomes by few patients were reported with Arthroscopic release done under general anesthesia as it is a invasive procedure [4]. An infrequently cited option is hydraulic joint capsule distension under local anesthesia (hydroplasty) [5]. It is also called as Distension arthrography (also known as hydrodilatation). The hydrodilatation procedure was first described by Andr en and Lundberg. This technique was developed in order to loosen the reported contraction and adhesion. It is based on the principle of injection into the glenohumeral joint under pressure. Fareed and Gallivan [6], initially reported in a case series of twenty patients that this is an office technique without arthrography, and the patients in this study noted immediate pain resolution, return of normal function and normal sleep.

However, despite the ubiquity of this condition and the advances in shoulder surgery over the last fourteen decades there are still many unknowns in deciding what the best treatment options are for this disease condition. In this study we evaluated the Range of movement and pain relief of shoulder following "Hydraulic distension under local anaesthesia" pre and post distension.

Material and methods

A prospective observational study was conducted in the department of orthopaedics at RLJ hospital attached to Sri Devaraj Urs Medical College between June 2018 to November 2019 for a period of 1.5 year. All the Patients with Peri arthritis shoulder and age above 30 years were included in the study. After obtaining the informed consent from the patients who agree to be part of study. Demographic data, History, Clinical Examination and details of investigations were recorded in study proforma, and then were taken for procedure. All the patients were got intraarticular Hydraulic distension with Normal saline. The surgeon had injected a single dose of 30-40 ml of the Normal saline or upto the ease of resistance felt during infiltration, along with steroid into the intraarticular area of the shoulder in an aseptic technique. Posterior Approach was used. 2 cm below the angle of the acromion and 2 cm medial to it (Mike walton). The needle is directed anteriorly and medially towards the coracoid process. 2 to 3 cm depth was reached with a 20 gauge needle. Mean joint depth would be 43.5 mm at posterior and 27.1 mm at anterior side. X rays, Ultrasound was done if necessary in doubtful cases of extravasation of fluid into the pericapsular area. Pendulum and range of movement exercise at home are advised for all the patients. Findings were recorded and outcomes were measured before the injection and during each follow-up at 3 weeks, 6 weeks and 12 weeks after procedure. The pain and functional scoring used as per "The society of American Shoulder and elbow surgeons". Before and after the intervention was assessed one way repeated measures ANOVA. P value < 0.05 was considered statistically significant. IBM SPSS version 22 was used for statistical analysis [7].

Results

The mean age was 52.68 ± 9.79 in the study population, ranged between 30 years to 80 years (95% CI 49.90 to 55.46). Among the study population, 36 (72%) were participants male and remaining 14 (28%) participants were female. Among the study population, 23 (46%) participants had dominant. Among the study population, 22 (44%)

participants had diabetes, 8 (16%) participants had hypertension and only 1 (2%) participant had IHD.

Table 1: Descriptive analysis of age age group gender side Comorbidities in study population (N=50)

Parameter	Frequency
Age	52.68 ± 9.79
Age Group	
30 to 39	3(6.00%)
40 to 49	18(36.00%)
50 to 59	15(30.00%)
60 to 69	12(24.00%)
≥70	2(2.00%)
Gender	
Male	36(72.0%)
Female	14(28.0%)
Side	
Dominant	23(46.0%)
Not dominant	27(54.0%)
Comorbidities	
DM	22(44.0%)
HTN	8(16.0%)
IHD	1(2.0%)
Nil	19(38.0%)

Table 2: Comparison of mean flexion abduction internal rotation external rotation on the time of presentation and follow up time periods (N=50)

Follow up time periods	Mean ± SD	P value
Flexion		
On the time of presentation	70.2 ± 23.6	<0.001
Immediately post distension	99.1 ± 25.83	
at 3 rd week	120.8 ± 23.81	
at 6 th week	140.98 ± 24.16	
at 12 th week	153.9 ± 21.48	
Abduction		
On the time of presentation	71.7 ± 27.91	<0.001
Immediately post distension	103.4 ± 25.28	
at 3 rd week	130 ± 26.86	
at 6 th week	145.4 ± 24.41	
at 12 th week	155.1 ± 22.05	
Internal Rotation		
On the time of presentation	28.3 ± 10.58	<0.001
Immediately post distension	47.5 ± 12.13	
at 3 rd week	62.1 ± 15.81	
at 6 th week	72.3 ± 15.16	
at 12 th week	79.3 ± 13.05	
External Rotation		
On the time of presentation	21.7 ± 5.77	<0.001
Immediately post distension	31.4 ± 5.63	
at 3 rd week	39.1 ± 6.6	
at 6 th week	46.4 ± 5.81	
at 12 th week	52.8 ± 6.16	

The mean flexion on the time of presentation was 70.2 ± 23.6 , it was 99.1 ± 25.83 at immediately post distension, it was 120.8 ± 23.81 at 3rd week, it was 140.98 ± 24.16 at 6th week and it was 153.9 ± 21.48 at 12th week. The difference in flexion at different follow up periods was statistically significant. (P value <0.001). The mean Abduction on the time of presentation was 71.7 ± 27.91 , it was 103.4 ± 25.28 at immediately post distension, it was 130 ± 26.86 at 3rd week, it was 145.4 ± 24.41 at 6th week and it was 155.1 ± 22.05 at 12th week. The difference in Abduction at different follow up periods was statistically significant. (P value <0.001). The mean internal rotation on the time of presentation was 28.3 ± 10.58 , it was 47.5 ± 12.13 at immediately post distension, it

was 62.1 ± 15.81 at 3rd week, it was 72.3 ± 15.16 at 6th week and it was 79.3 ± 13.05 at 12th week. The difference in internal rotation at different follow up periods was statistically significant. (P value <0.001). The mean external rotation on the time of presentation was 21.7 ± 5.77 , it

was 31.4 ± 5.63 at immediately post distension, it was 39.1 ± 6.6 at 3rd week, it was 46.4 ± 5.81 at 6th week and it was 52.8 ± 6.16 at 12th week. The difference in external rotation at different follow up periods was statistically significant. (P value <0.001).

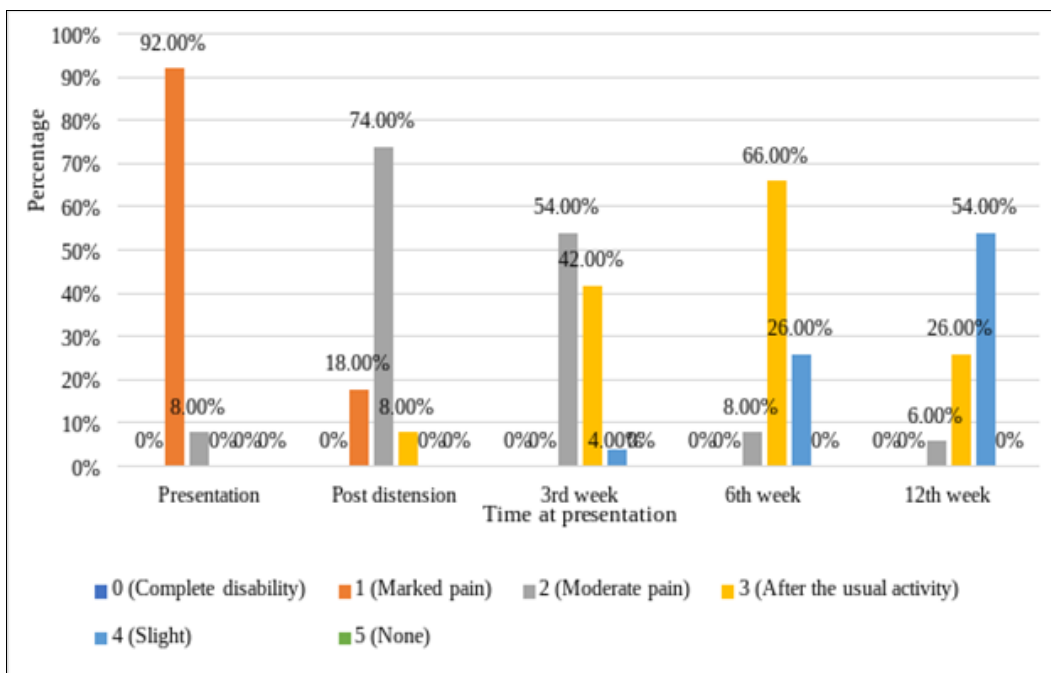


Fig 1: Clustered bar chart of pain score in the study population (N=50)

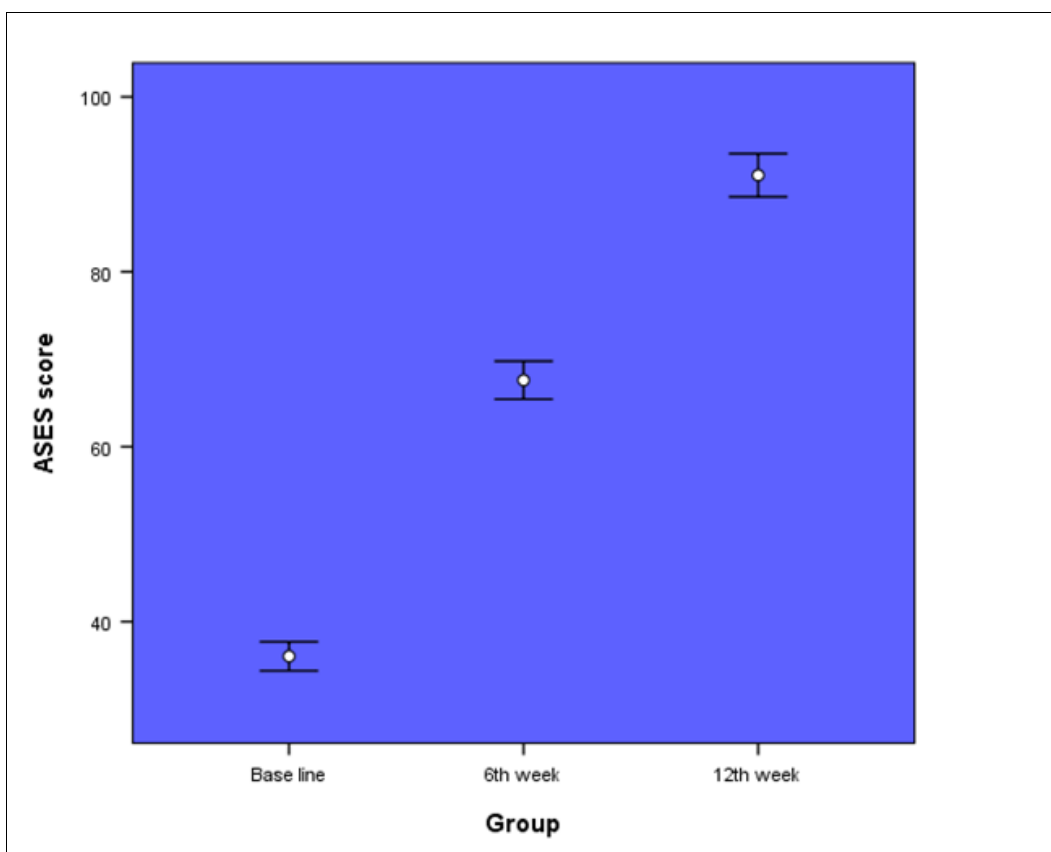


Fig 2: Error bar chart of comparison of mean ASES score across the different time periods (N=50)

Discussion

Adhesive capsulitis is an extremely disabling disorder, characterized with pain and remitting shoulder stiffness and pain. Clinically it has symptoms of severe pain and insidious shoulder stiffness, which results in limited passive and active

external rotation and forward flexion. Recently arthroscopic treatment has also been recommended for this condition. It involves the intra- articular injection of a large amount of normal saline to distend and rupture the capsular adhesions. In this study we evaluated the Range of movement and pain

relief of shoulder following “Hydraulic distension under local anaesthesia along with a steroid” pre and post distension.

Total 50 patients were included in the study and were evaluated post operatively followed by 3 weeks, 6 weeks and 12 weeks after procedure. The average age of the study population was 52.68 ± 9.79 , ranging between 30 years to 80 years (95% CI 49.90 to 55.46). It is almost similar to the study conducted by Buchbinder *et al.* [8] who reported a slightly higher average age of 57.2 years in their study. In the present study 36 (72%) participants were males and 14 (28%) participants were females. Age and sex distribution reported in the literature have been widely variable, according to Segmuller *et al.* [9] ages ranging from 22 years to 85 years were reported. In a study by Shah *et al.* [10] reported that with percentage of female subjects ranged from 48% to 84% which is contradicting our study because of the different socio demographic characteristics of the area.

Majority of the participants 18(36%) were in 40 to 49 years age group followed by 15(30%) in 50 to 59 years age group, 12(24%) in 60 to 69 years age group, 3(6%) in 30 to 39 years age group, 2(4%) were greater than 70 years. Among the study population, 23 (46%) participants had dominant side involved. In a study conducted by Mishra *et al.* [11] 8 patients ((10%) had bilateral involvement while in 33 patients (41 %) had involvement of the dominant side that is right shoulder, while 39 patients (49 %) were found to have left shoulder involvement.

Few patients were found to have certain associated conditions like 22 (44%) participants had diabetes, 8 (16%) participants had hypertension and only 1 (2%) participant had IHD in our study. Similarly Mishra *et al.* [11] in their study had 12 patients had diabetes mellitus, 10 patients had hypertension, 13 patients had osteoarthritis of knee, 1 patient diagnosed with peptic ulcer, and 3 patients of bronchial asthma were seen.

In the current study, The mean flexion on the time of presentation was 70.2 ± 23.6 , it was 99.1 ± 25.83 at immediately post distension, it got further improved from the average of 120.8 ± 23.81 at 3rd week, to 140.98 ± 24.16 at 6th week and 153.9 ± 21.48 at 12th week. The difference in flexion at different follow up periods was statistically significant. (P value <0.001). In a study done by Vad *et al.* [12] range of flexion improved from a predistention mean of 92° to a postdistention mean of 110° and to 111° at 1 year after distention. According to Baums *et al.* [13] mean flexion showed an improvement to 150° (6 weeks) and respectively 160° (36 months) compared to 85° pre operatively.

The mean Abduction on the time of presentation in the present study was 71.7 ± 27.91 , it got better by 103.4 ± 25.28 immediately post distension, further improved by 130 ± 26.86 at 3rd week, 145.4 ± 24.41 at 6th week and it 155.1 ± 22.05 at 12th week. The difference in Abduction at different follow up periods was statistically significant. (P value <0.001). In a study done by Vad *et al.* [12] range of abduction improved from a predistention mean of 83° to a postdistention mean of 107.1° and to 106.8° at 1 year postdistention. Baums *et al.* [13] abduction improved from a mean of 70° preoperatively to a mean of 140° (6 weeks) and respectively 150° at latest follow-up (36 months).

In the current study the mean internal rotation on the time of presentation was 28.3 ± 10.58 , it was 47.5 ± 12.13 immediately post distension, it was 62.1 ± 15.81 at 3rd week, it was 72.3 ± 15.16 at 6th week and it was 79.3 ± 13.05 at 12th week. The difference in internal rotation at different follow up periods was statistically significant. (P value <0.001). According to Baums *et al.* [13] IR shows an improvement to a

mean of 50° (6 weeks) and of 60° in the final examination.

The mean external rotation on the time of presentation was 21.7 ± 5.77 , it was 31.4 ± 5.63 at immediately post distension, it was 39.1 ± 6.6 at 3rd week, it was 46.4 ± 5.81 at 6th week and it was 52.8 ± 6.16 at 12th week. The difference in external rotation at different follow up periods was statistically significant. (P value <0.001). Baums *et al.* [13] Average ER in adduction improved from 10° preoperatively to 45° (6 weeks) and respectively 65° in the latest follow-up assessment.

In a study conducted by Mao *et al.* [14] on 12 patients flexion, Abduction, Internal rotation, External rotation among acute cases pre operatively was 111 ± 10 , 101 ± 18 , 64 ± 12 , 24 ± 8 respectively. Post operatively it was 153 ± 11 , 143 ± 12 , 83 ± 7 , 69 ± 15 respectively. The difference in ROM pre and post operatively was statistically significant. (P value <0.001). Flexion, Abduction, Internal rotation, External rotation among chronic cases pre operatively was 113 ± 20 , 103 ± 25 , 60 ± 8 , 29 ± 11 respectively. Post operatively it was 148 ± 16 , 149 ± 13 , 86 ± 9 , 63 ± 13 respectively. The difference in ROM pre and post operatively was statistically significant. (P value <0.001).

Conclusion

Hydraulic distension is a cost effective, safe, reliable, modality in treating the painful, chronically distressing adhesive capsulitis. This treatment can be practiced as an out-patient therapy, without any specialized equipments. It has absolutely no side effects, when performed with a right technique under aseptic precautions. Hence, we conclude that hydraulic distension under local anesthesia with steroid can be considered as a first line management option in patients with frozen shoulder.

References

- Jacobs LG, Barton MA, Wallace WA, Ferrousis J, Dunn NA, Bossingham DH. Intra-articular distension and steroids in the management of capsulitis of the shoulder. *BMJ*. 1991; 302(6791):1498-501.
- Uppal HS, Evans JP, Smith C. Frozen shoulder: A systematic review of therapeutic options. *World J Orthop*. 2015; 6(2):263-8.
- Jacobs LG, Smith MG, Khan SA, Smith K, Joshi M. Manipulation or intra-articular steroids in the management of adhesive capsulitis of the shoulder? A prospective randomized trial. *J Shoulder Elbow Surg*. 2009; 18(3):348-53.
- Manske RC, Prohaska D. Clinical commentary and literature review: diagnosis, conservative and surgical management of adhesive capsulitis. *Shoulder Elbow*. 2010; 2(4):238-54.
- van der Windt DAWM, Koes BW, Devillé W, Boeke AJP, de Jong BA, Bouter LM. Effectiveness of corticosteroid injections versus physio therapy for treatment of painful stiff shoulder in primary care: randomised trial. *BMJ*. 1998; 317:1292-6.
- Fareed DO, Gallivan WR, Jr. Office management of frozen shoulder syndrome. Treatment with hydraulic distension under local anesthesia. *Clin Orthop Relat Res*. 1989(242):177-83.
- IBM Corp. Released 2013. IBM SPSS Statistics for Windows, Version 22.0. Armonk, NY: IBM Corp.
- Buchbinder R, Green S, Forbes A, Hall S, Lawler G. Arthrographic joint distension with saline and steroid improves function and reduces pain in patients with painful stiff shoulder: results of a randomised, double

- blind, placebo controlled trial. *Ann Rheum Dis.* 2004; 63(3):302-9.
9. Segmüller HE, Taylor DE, Hogan CS, Saies AD, Hayes MG. Arthroscopic treatment of adhesive capsulitis. *J Shoulder Elbow Surg.* 1995; 4(6):403-8.
 10. Shah MA, Khan I. Comparison Between Manipulation under Anesthesia and Hydraulic Distension for Treatment of Frozen Shoulder. *Ann King Edward Med Univ.* 2008; 14(1):26.
 11. Mishra AN, Mishra S, Dhungana HN. A study of clinical evaluation of effectiveness of hydraulic distension of shoulder in the management of frozen shoulder. *Int J Orthod.* 2017; 3(2):675-7.
 12. Vad VB, Sakalkale D, Warren RF. The role of capsular distention in adhesive capsulitis. *Arch Phys Med Rehabil.* 2003; 84(9):1290-2.
 13. Baums MH, Spahn G, Nozaki M, Steckel H, Schultz W, Klinger HM. Functional outcome and general health status in patients after arthroscopic release in adhesive capsulitis. *Knee Surg Sports Traumatol Arthrosc.* 2007; 15(5):638-44.
 14. Mao CY, Jaw WC, Cheng HC. Frozen shoulder: correlation between the response to physical therapy and follow-up shoulder arthrography. *Arch Phys Med Rehabil.* 1997; 78(8):857-9.