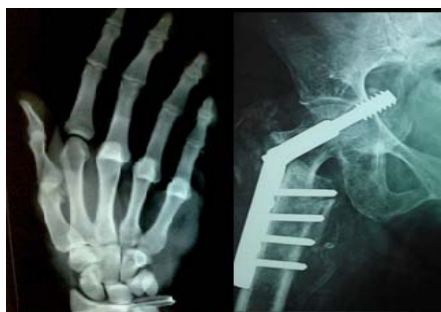



International Journal of Orthopaedics Sciences

ISSN: 2395-1958
IJOS 2016; 2(4): 72-76
© 2016 IJOS
www.orthopaper.com
Received: 11-08-2016
Accepted: 12-09-2016

Dr. Parvataneni Prathap
Sri Devraj Urs Medical College,
Tamaka, Kolar, Karnataka,
India

Dr. Arun HS
Sri Devraj Urs Medical College,
Tamaka, Kolar, Karnataka,
India

Dr. Anvesh Kondlapudi
Sri Devraj Urs Medical College,
Tamaka, Kolar, Karnataka,
India

Dr. Hariprasad S
Sri Devraj Urs Medical College,
Tamaka, Kolar, Karnataka,
India

Functional outcome in surgical management of Bi- malleolar fractures in adults

**Dr. Parvataneni Prathap, Dr Arun HS, Dr. Anvesh Kondlapudi and
Dr. Hariprasad S**

DOI: <http://dx.doi.org/10.22271/ortho.2016.v2.i4b.11>

Abstract

Background: Malleolar injuries are the most common significant lower extremity fractures. These injuries gain importance, because the whole body weight is transmitted through the ankle, and locomotion depends on the stability of the ankle. Open reduction and internal fixation have become the mainstay of treatment for most of the unstable bimalleolar fractures, as these operative methods restores the anatomy, biomechanics and contact loading characteristics of the ankle.

Objectives: To study the functional outcome of surgically managed bimalleolar fractures of ankle in adults.

Methods: A prospective study of 30 cases of bimalleolar fractures of ankle in adults, managed surgically by various techniques in During the period from December 2014 to May 2016 were studied, satisfying the inclusion and exclusion criteria were studied. The functional outcome was evaluated using the *Biard and Jackson's* ankle scoring system.

Results: In our study we achieved 86.6% excellent to good results, 6.6% fair results, 6.6% poor results. The results were comparable to other studies.

Interpretation & Conclusion: The operative results were satisfactory in 86.6% cases, with good to excellent functional outcome. Excellent results are obtained with stable fixation of fracture. Cancellous screws or malleolar screws are far better in internal fixation of medial malleolus compared to Kirschner - wire fixation and lateral plating was the best for fibular fractures. Good functional results are obtained by surgical management of bimalleolar ankle fractures. Early weight bearing and mobilisation is achieved in these patients. Anatomical reduction with restoration of the articular congruence is essential in all intra articular fractures, more so, if a weight bearing joint like ankle is involved. Open reduction and internal fixation restores the articular congruity of the ankle joint. TBW done for many PER and PA injuries showed promising results comparable to that with screw fixation and also lesser reports of skin irritation at the wound site. It is the method preferred for small transverse fragments and osteoporotic bones of both malleoli especially in the elderly.

Keywords: Malleolus, plating, cancellous, biomechanics, medial, TBW

Introduction

Sir Robert Jones said, "Ankle is the most injured joint of the body but the least well treated"^[1]. Ankle injuries gain importance because body weight is transmitted through the joint and locomotion depends upon the stability of it. They are usually mixed injuries, ligamentous and bony; and each injury is an end result of the sequence of ligamentous and bony failure due to deforming forces. Malleolar fracture have varied presentations which have given rise to a wide variety of classification systems, of which two are in vogue: Lauge-Hansens and Danis-Weber classification.

Malleolar fractures are one of the most common fractures in orthopaedic traumatology. As with all intra articular fractures, malleolar fractures necessitate accurate reduction and stable internal fixation. When malleolar fractures are not reduced accurately they may lead to post traumatic painful restriction of motion or osteoarthritis or both^[2].

As for the treatment of malleolar fractures, many of them which are stable are reduced by conservative treatment and have given good result. The other unstable displaced and open fractures require open reduction internal fixation. The superiority of ORIF over closed treatment have been thoroughly demonstrated in literature^[3].

The operative method restores the anatomy and contact-loading characteristic of the ankle. Additional advantages include easier rehabilitation without a cast, early mobilization and earlier weight bearing^[4].

Correspondence

Dr. Anvesh Kondlapudi
Sri Devraj Urs Medical College,
Tamaka, Kolar, Karnataka,
India

However all studies have not obtained good results in cases of bimalleolar fractures. The purpose of this study is to assess the functional outcome and results of surgical treatment of malleolar fractures.

Methodology

Patients admitted from December 2014 to May 2016 to the department of orthopaedics with bimalleolar fractures satisfying the inclusion criteria will be included in the study and with follow up from the time of admission to a minimum of 6 months of postoperative period will be done (minimum of 30 cases will be studied).

Inclusion Criteria

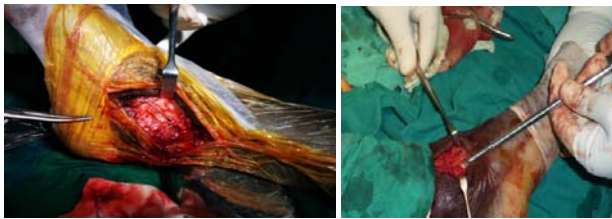
- All closed fractures.
- Open type 1, 2, 3a (Gustilo-Anderson).
- Above 18 years.

Exclusion Criteria

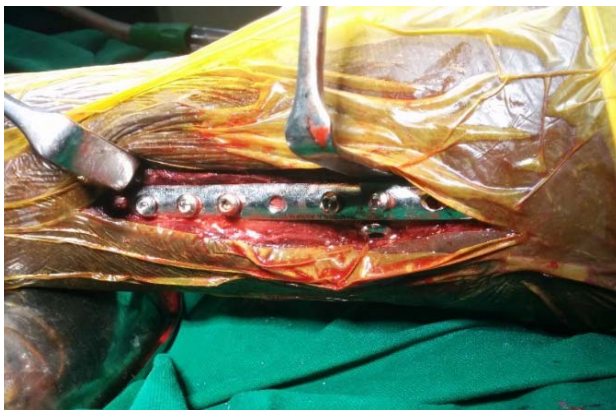- With associated Pilon fracture.
- Patients unfit for surgery.
- Patients with minimally displaced mono-malleolar fractures, avulsion fractures and stable fractures

Operative Technique

In our study tension band wiring, malleolar screw, K wires, cancellous screws were used for fixing medial malleolus. One third tubular plate and K wires were used to fix lateral malleolus



Tension band wiring for medial malleolus malleolar screw for medial malleolus



One third tubular plate for lateral malleolus Post – Operative Protocol

Non-weight bearing gait was started from first or the second postoperative day. Partial weight bearing was started after the removal of the cast (after clinical and radiological signs of union become evident). Active exercises of the ankle was advised. In patients with syndesmotic screw fixation, weight bearing was delayed till screw removal. Follow up of cases was done at regular intervals of 6 weeks for minimum of 6 months. Using *Biard and Jackson's* [5] ankle scoring system.

Observation and Results

In our series 30 bimalleolar fractures of ankle, treated by surgical methods during the period of December 2014 to May 2016 were studied. The following were the observations made and the available date analyzed as follows.

In our study majority of the patients were male (83.3%), most of the patients were in the age group of 19-30 years with mean age of 37.3 years. Majority of the patients sustained these injuries following road traffic accidents. Supination external rotation injury is the most common fracture type in this study, 3 patients had associated syndesmotic injury.

Treatment of Individual Fractures

A) Medial Malleolus Fracture

Majority of the medial malleolus fractures were fixed with malleolar screws 16 (53.3%). In the rest of the cases cancellous screws, tension band wiring and K wires were used.

Implants	Malleolar Screw	Cancellous Screw	TBW	K Wire
No of Cases	16	6	3	5
Percentage	53.3	20	10	16.6

B) Lateral Malleolus Fracture

Majority of the lateral malleolus fractures were fixed with one third tubular plate 21 (70%). Rest of the fractures were fixed with K wires and cancellous screws.

Implant	Plating	K Wire	Cancellous Screw
No of Cases	21	7	2
Percentage	70	23.3	6.6

C) Syndesmotic Fixation

In 3 cases (10%) syndesmotic injury was noted and in these cases it was fixed with a fully threaded screw. Weight bearing was delayed till screw removal which was done at 6-8 weeks.

Union

In our study average time taken for union was 10.6 wks. Most of the cases showed union between 8- 14 wks.

Union (WKS)	8 WKS	10 WKS	12 WKS	14 WKS	16 WKS
No of cases	9	10	5	5	1

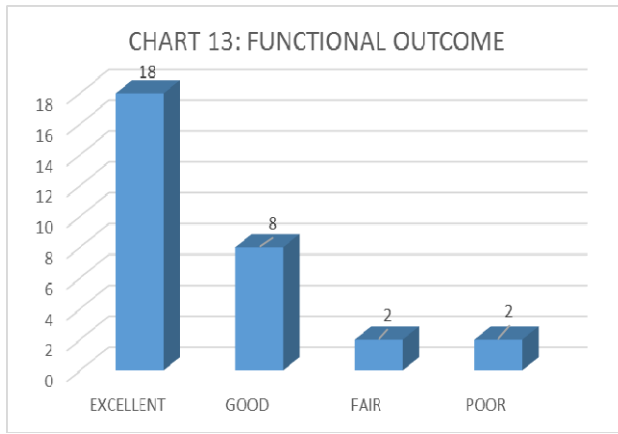
Complications

In our series 5 cases (16.6%) had complications. 2 patients had superficial infection, 2 patients had deep infection and 1 patient had delayed union. Infections were managed with debridements and antibiotics. Delayed union fracture medial malleolus is treated with continued immobilization, which eventually united without surgical intervention.

Complications	No of Cases	Percentage
Superficial Infection	2	6.6
Deep Infection	2	6.6
Delayed Union of Medial Malleolus #	1	3.3

12) Functional Results

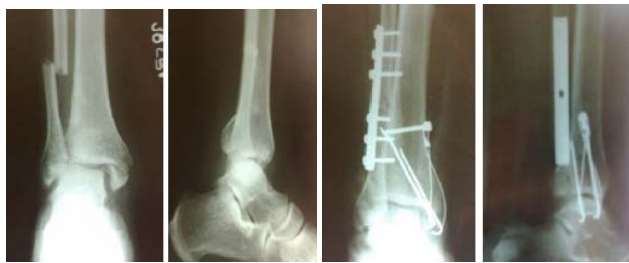Functional Score	No of Cases	Percentage
Excellent	18	60
Good	8	26.6
Fair	2	6.6
Poor	2	6.6



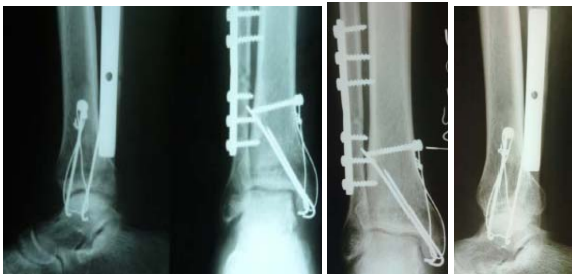In this present study 30 patients with bi malleolar fractures were treated surgically. Excellent results were achieved in 18 cases (60%), good in 8 cases (26.6%), fair in 2 cases (6.6%), poor in 2 cases (6.6%). Excellent results were seen in most of the bi malleolar fractures, 4 patients who had fair to poor results were seen in cases with delayed union of medial malleolus, superficial and deep infection. The patients who had poor results had mild pain during their activities of daily living, diminution in their ability to run and do work, reduced motion of ankle and narrowing of joint space.

X Ray and Clinical Photographs

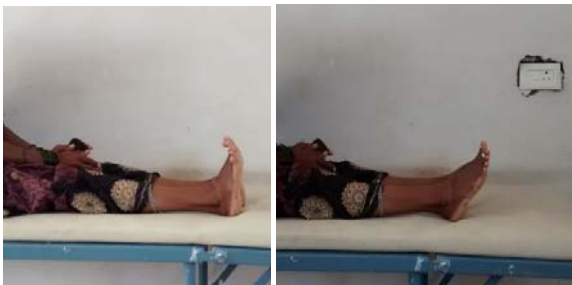Case 2:



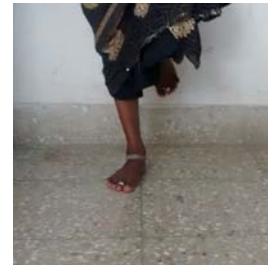Pre op post op



Union at 10 WKS 6 months follow up

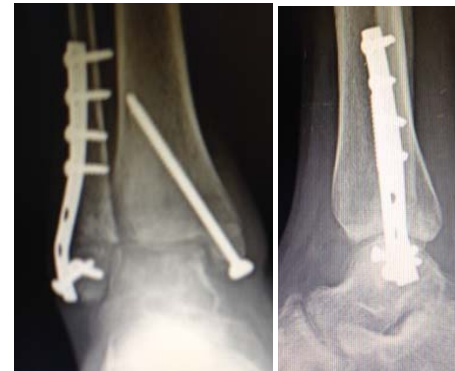
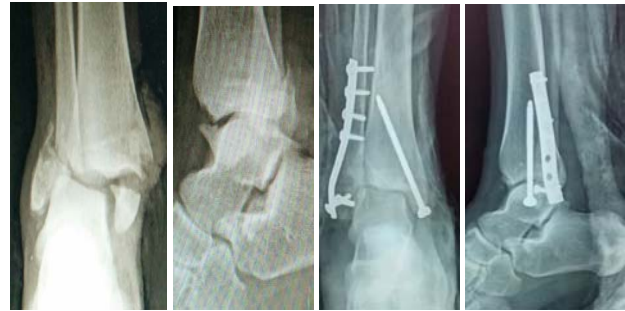
Dorsiflexion of ankle plantar flexion of ankle

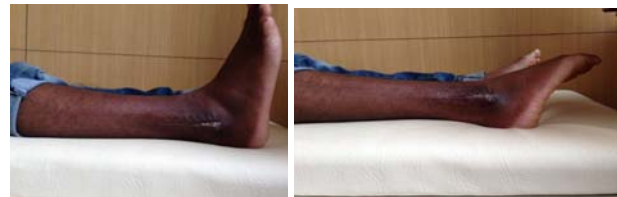

Standing on one leg

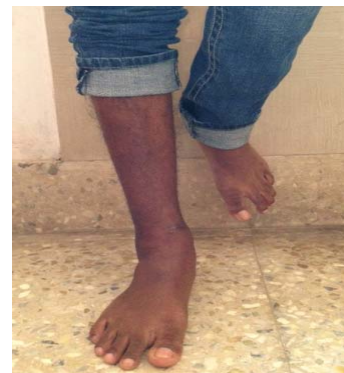CASE: 5



Pre op post op union at 10 WKS



Ankle Dorsiflexion Ankle Plantar Flexion



Standing on one Leg

Discussion

There has been an increase in the prevalence of bi malleolar fractures over the last two decades both in the young, active patients and in the elderly [6]. Methods to restore function and to prevent arthritis are either closed treatment, which includes manipulative reduction and immobilization in plaster cast or open reduction with internal fixation. Burnwell and Charnley showed that anatomical reduction and rigid fixation led to early return to Function [7].

There has been gradual evolution in management of ankle fractures due to improved analysis of biomechanics, improvement in fixation techniques and analysis of results of recent studies. The goal of treatment is to provide fracture union with painless full motion of ankle and with anatomical restoration of the injured ankle.

Closed method of treatment is often inadequate in restoring the anatomy and biomechanics of ankle in unstable malleolar ankle fractures. Conversely, open reduction with internal fixation is an excellent method for restoration of normal anatomy of joint.

Several studies indicated that, internal fixation of displaced malleolar fractures of ankle provides better results [7, 8, 9]. The treatment of malleolar fractures with accurate open reduction and stable internal fixation using AO method and principles was found to give a higher percentage of excellent and good results [10]. This study supports these conclusions.

In the current study, we have 30 patients with bimalleolar ankle fractures, who were operated upon. All patients were followed up with minimum period of 6 months.

In our study, fractures were commoner in the 19-30 yrs age group, with mean age being 37.3 yrs. Our findings are comparable to the studies made by, Beris *et al* [10], Roberts RS [11], Baird and Jackson [5] and Lee *et al* [12].

In this present study, Lauge-Hansen classification system was used for operative evaluation. The most common type of injury was supination-external rotation (46.6%), followed by pronation-abduction injury (33.3%), in accordance with by Roberts RS, Beris *et al*, Baird and Jackson.

The results in current study were compared with that of Burnwell & Charnley, Colton [13], De souza *et al*, Beris *et al*. In Colton series, 70% of the patients had a good to excellent results. Burnwell & Charnley in their series of 132 patients, 102 (77.3%) had good results, 16% had fair results and 6% were found to poor score.

In De souza series, 150 cases of ankle fractures treated by open reduction and internal fixation using AO/ASIF method, obtained 90% good results. In a study by Beris *et al*, of 144 patients with ankle fractures, 105 (74.3%) had good to excellent results.

The functional results of the present study were comparable with that of the above cited studies, with 86.6% had good to excellent results, 6.6% had fair results and poor results in 6.6%.

Study	Good to Excellent	Fair	Poor
Burnwell & Charnley	102 (77%)	22 (17%)	8 (6%)
Colton	18 (70%)	4 (15%)	4 (15%)
Beris <i>et al</i>	105 (74.3%)	21 (14.6%)	16 (11.1%)
De souza	135 (90%)	9 (6%)	6 (4%)
Present study	26 (86.6%)	2 (6.6%)	2 (6.6%)

Most authors have stated that anatomical reduction of displaced medial malleolus ensures correction of talar displacement and is of paramount importance in treating

unstable fractures [14]. However, Heller *et al* [15]. State that talus is more accurately repositioned in mortise by anatomical reduction of lateral malleolus.

Observation in this study support the contention of Yablon *et al* [15] that lateral malleolus is the key to the anatomical reduction of bimalleolar fractures, because the displacement of the talus faithfully followed that of the lateral malleolus. Poor reduction of the lateral malleolus fracture would result in persistent lateral displacement or residual shortening. This does not necessarily lessen the importance of medial malleolus, but it does serve to emphasize that the lateral malleolus should no longer be ignored. In the current study, one patient with poor outcome didn't have anatomical reduction of the medial malleolus possibly due to soft tissue interposition.

Lateral malleolus can be fixed by various methods. Lateral plate, as advocated by AO group has become widely accepted for treatment of fibular fracture [15]. Hughes *et al* [16] recommended that lateral malleolus should be fixed first. The medial malleolus is then inspected for stability and fixed if necessary. This allows minimal postoperative immobilization and rapid recovery of function.

In this study, the functional outcome was better in patients who underwent stable internal fixation of the medial malleolus by cancellous or malleolar screw. The results were not equally satisfactory in those patients who had less rigid fixation of the medial malleolus using only Kirschner wires. Tension band wiring of the medial malleolus gave results equivalent of those fixed with screws and lesser reports of skin irritation which was more frequent in those patients with screw fixation.

In many fractured ankles, syndesmosis is stable after reduction and internal fixation of fibula fracture and medial malleolar fracture. Yablon [15] stated that anatomical reduction of the fibula is the key factor in achieving good outcome of the treatment of ankle fractures with syndesmotic disruption. In the current series, three patients underwent trans-syndesmotic screw fixation. Excellent outcome was seen in one patient and good outcome was seen in two patients.

Although early mobilization was advocated by AO group, other studies have found no significant difference in the results produced after early mobilization. In the current study, immobilization was done for 4 weeks. Partial weight bearing was advised for those with early radiological signs of union and full weight bearing when the signs of union were complete. The range of motion of ankle was reduced initially, but improved over few weeks.

In 30 of our patients there was no instability of ankle or subtalar joints, because we allowed sufficient time for the soft tissues around the ankle to heal. We preferred postoperative immobilization rather than allowing active ankle exercise as there was no difference in the results after 6 months of follow up.

Bray noted that incidence of complications are less in patients who underwent immediate surgery when compared to those who underwent delayed surgery. Which also holds good in our study.

Fair to poor results in the current series were seen due to wound infection and delayed union of medial malleolus. Restricted activity level and range of movement without radiological evidence of arthritis was noted in four patients.

Majority of the patients (86.6%) had good to excellent results in the current study, similar to what was observed in other series like Burnwell & Charnley, Colton, De souza *et al*, Beris *et al*.

The treatment of bimalleolar fractures with accurate open reduction and stable internal fixation using AO method and principles was found to give a high percentage of excellent and good results. This study supports these conclusions and was comparable with those in other studies.

Conclusion

In this review, the 30 cases of bimalleolar fractures of ankle that were unstable displaced or both, were treated surgically by open reduction and internal fixation.

Unstable bimalleolar ankle fractures are common due to road traffic accidents. Ankle injuries are common in middle aged men. Age groups between 19-30 years were most commonly injured. The mean age of present study was 37.3 years. Bimalleolar fractures more common in male than female. Majority of them, were caused by supination-external rotation (37.5%) injury. Understanding the mechanism of injury is essential for anatomical reduction and fixation. Fibular alignment (length, rotation) has to be maintained for lateral stability of the ankle. Anatomical reduction with restoration of the articular congruence is essential in all intra articular fractures, more so, if a weight bearing joint like ankle is involved. Open reduction and internal fixation restores the articular congruity of the ankle joint. The operative results were satisfactory in 86.6% cases, with good to excellent functional outcome. Functional results were much better in younger age groups and men. Fair to poor results were seen in those bimalleolar fractures associated with wound infection and those with unsatisfactory reduction of fracture fragments. Excellent results are obtained with stable fixation of fracture. Cancellous screws or malleolar screws are better in internal fixation of medial malleolus compared to Kirschner -wire fixation and lateral plating was the best for fibular fractures. TBW done for PER and PA injuries showed promising results comparable to that with screw fixation and also gave lesser reports of skin irritation at the wound site. It is the method preferred for small transverse fragments and osteoporotic bones of both malleoli especially in the elderly. Functional results improve when the normal bend of the lateral malleolus, is restored while plating. Chances of non-union due to soft tissue interposition were avoided by surgical treatment. Delayed union of two cases, were possibly due to unsatisfactory reduction at time of surgery. Good functional results are obtained by surgical management of bimalleolar ankle fractures. Early weight bearing and mobilization is achieved in these patients.

Hence we conclude that, surgical management of bimalleolar ankle fractures provides good functional outcome. By stable surgical fixation of the fracture, early mobilization can be achieved.

References

1. Shelton Mar Vin L. Complication of fractures and dislocation of the ankle. In: Complications in orthopaedic surgery, Chapter 23, 3rd edn., ed. EPPS, Charles H, Philadelphia: J.B. Lippincott Company. 1994; I:595-648.
2. Beris AE, Kabbani KT, Xenakis TA, Mitsionis G, Soucacos PK, Soucacos PN. Surgical treatment of malleolar fractures – a review of 144 patients. Clin Orthop Related Research. 1997; 341:90-98.
3. Weber MJ. Ankle fractures and dislocations. In: Operative orthopaedics, Chapter-50, 2nd edn., Ed. Chapman MW, Madison M. Philadelphia : J.B. Lippincott Company. 1993; 3:731-748.
4. Geissler WB, Tsao AK, Hughes JL. Fractures and injuries

- of the ankle. In: Rockwood and Green's fractures in adults. 4th ed. Lippincott Raven. 1996, 2201-66.
5. Baird AR, Jackson TS. Fractures of the distal part of the fibula with associated disruption of the deltoid ligament. J Bone Joint Surg. 1987; 69A:1346-52.
6. Daly PJ, Fitzgerald RH, Melton LJ, Lstrup DM. Epidemiology of ankle fractures. Acta Orthopaedica Scandinavica, 1987; 58:539-44.
7. Burwell HN, Charnley AD. The treatment of displaced fractures of ankle by rigid internal fixation and early joint movement. J Bone Joint Surg. 1965; 47B:634-60.
8. De Souza LJ, Gustilo RB, Meyer TJ. Results of operative treatment of displaced external rotation-abduction fractures of ankle. J Bone Joint Surg. 1985; 67A:1066-74.
9. Cimino W, Ichtertz D, Silabaugh P. Early mobilization of ankle fracture after open reduction and internal fixation. Clin Orthop, 1991; 267:152-6.
10. Beris AE, Kabbani KT, Xenakis TA, Mitsionis G, Soucacos PK, Soucacos PN. Surgical treatment of malleolar fractures – a review of 144 patients. Clin Orthop Related Research. 1997; 341:90-98.
11. Roberts RS. Surgical treatment of displaced ankle fractures. Clin Orthop. 1983; 172:164-70.
12. Lee Yih-Shiunn, Huang, Chun-Chen NSP, Chen, Cheng-Nan, LinChien-Chung. Operative treatment of displaced lateral malleolar fractures: The Knowles pin technique. J Orthop Trauma. 2005; 19(3):192-97.
13. Colton CL. The treatment of Dupuytren's fracture dislocation of the ankle. J Bone Joint Surg, 197; 53B:63-71.
14. Hanssen SH, Bremerskov V, Barkgaard N. Ankle fractures treated by fixation of medial malleolus alone. Acta Orthopaedica Scandinavia. 1978; 49:211-14.
15. Yablon IG, Heller FG, Shouse L. The key role of lateral malleolus in displaced fractures of the ankle. J Bone Joint Surgery. 1977; 57A:169-173.
16. Hughes J. The medial malleolus in ankle fractures. Orthopaedic Clinics of North America. 1989; 11(3):649-660.