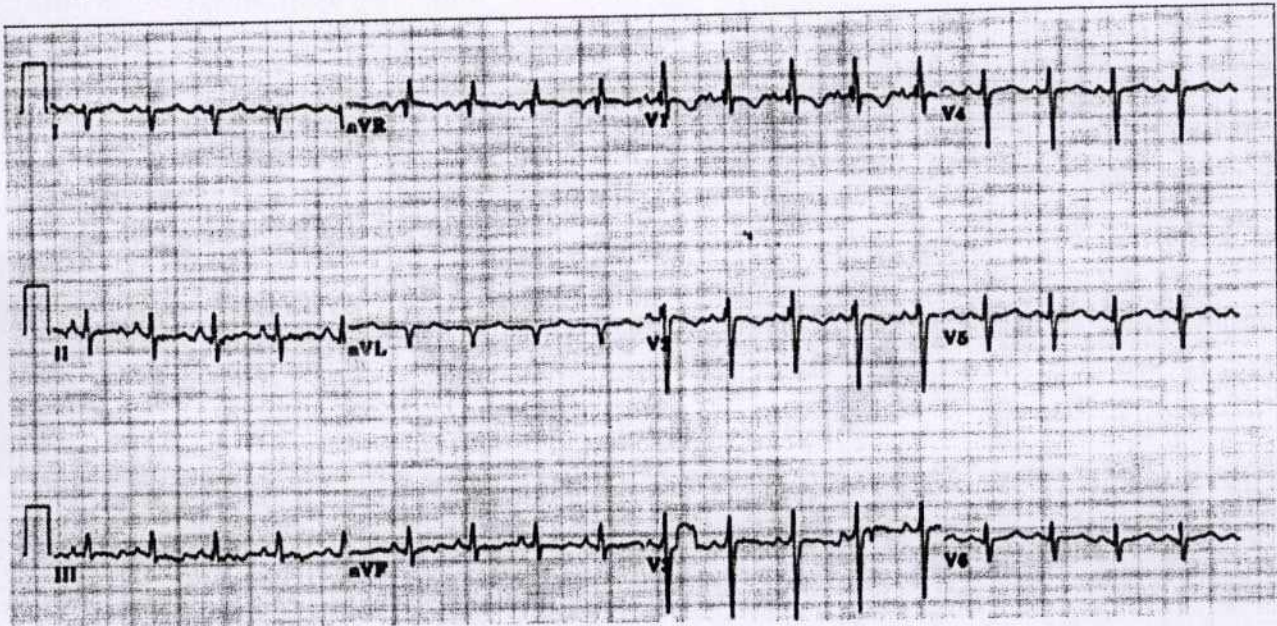


ECG With No Prior Heart or Lung Disease

ECG in a 25 year male patient with right shoulder pain and history of alcohol abuse with no prior history of heart or lung disease



Q.1 What best explains all abnormalities in this ECG?

1. Sinus rhythm
2. Left atrial enlargement
3. Right atrial enlargement
4. Right ventricular hypertrophy
5. Left ventricular hypertrophy
6. All of the above
7. None of the above.

Q.2 Is this ECG helpful clinically in guiding further management?

1. Yes
2. No

Corresponding Author:

Dr. Venkatesh T.K.

Department of Medicine,
Sri Devaraj Urs Medical College,
Tamaka, Kolar - 563101, Karnataka, India.

Email: venkateshtekur@yahoo.com

Mobile No: 9844075579

Answer on page No. 49

Answer to Quiz (Page No. 46)

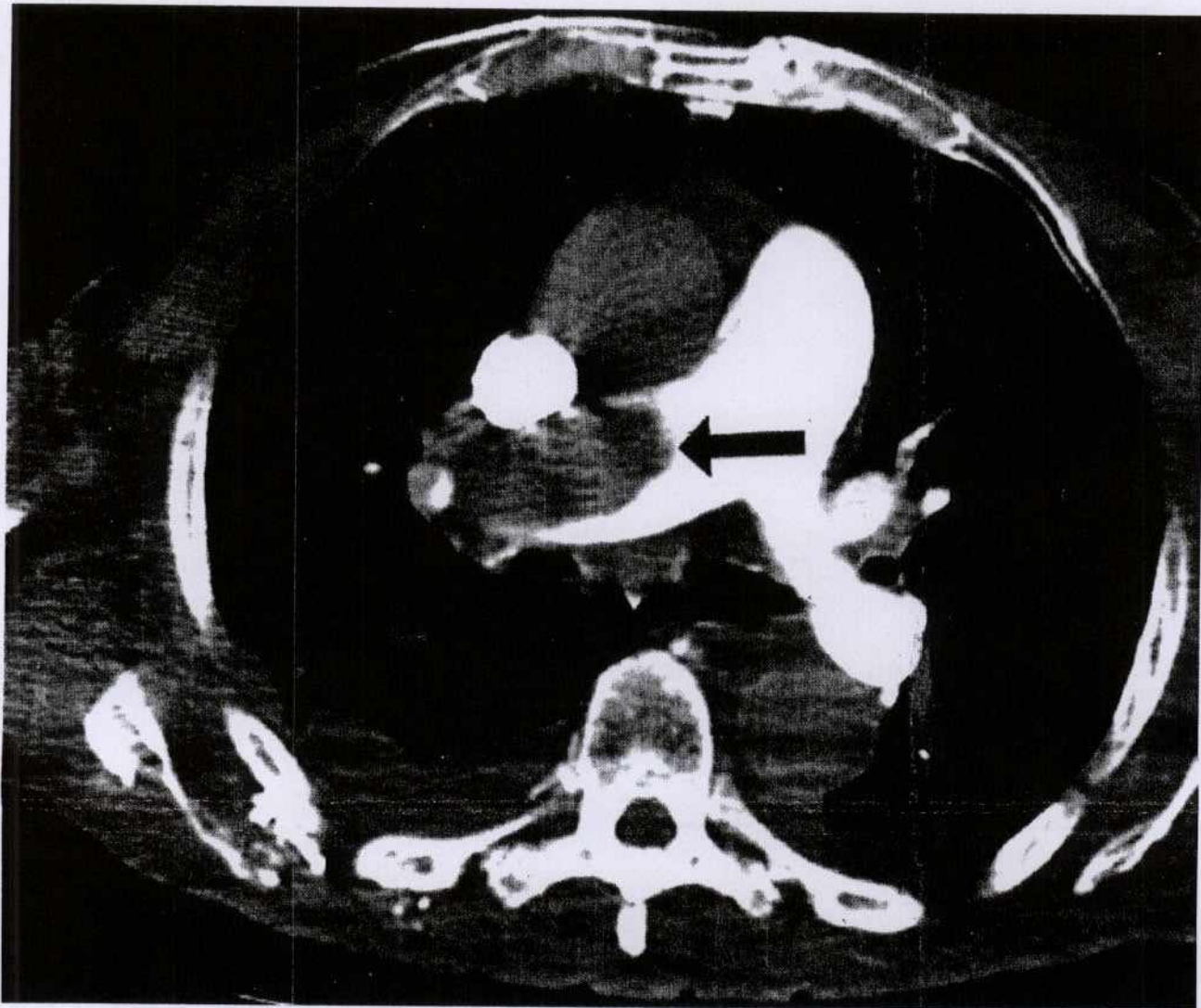
Q.1 Answer: 4. Right ventricular hypertrophy

ECG shows right axis deviation of QRS Complex in the frontal leads. There are few causes of right axis deviation of QRS complex in the adult. Some of them are Right ventricular hypertrophy, Left posterior fascicular block and Dextrocardia. The tall R in V1 and deep S in V6 along with right axis deviation and incomplete RBBB(rsR') indicate Right ventricular hypertrophy. There are also non specific ST-T changes noted.

Q.2 Answer: 1. Yes

With no previous history suggestive of cardiac or lung disease, such an acute presentation with features suggestive of Right ventricular hypertrophy raises a strong possibility of **Acute Pulmonary Embolism**. A bedside echocardiogram showed enlarged Right Atrium and Right ventricle with a pulmonary artery pressure of 70 mm Hg.

Soon a CT-Pulmonary Angiogram performed confirmed Acute Pulmonary Embolism.



Source of Support: Nil Conflict of Interest: Nil